

## **The Use of Costochondral Grafts in the Management of Temporomandibular Joint Ankylosis**

AYMAN A. SHAKER, M.D.

*The Department of Plastic and Reconstructive Surgery, Faculty of Medicine, Ain Shams University.*

### **ABSTRACT**

Costochondral grafts have gained increasing popularity in reconstruction of temporomandibular joint ankylosis. This is a report on the long term follow-up of 16 patients (13 growing and 3 non growing) who underwent reconstruction of the temporomandibular joint. Ten patients had bilateral ankylosis and six had unilateral ankylosis. The causes of ankylosis were mostly traumatic. Our operative protocol included excision of the ankylotic block through pre-auricular incision followed by immediate costochondral grafting. Fixation of the graft was done by screws or interosseous wires with intermaxillary fixation for 4-6 weeks. Pre-operative maximal incisal opening was ranging from 0-12 mm with the majority of them less than 5 mm. Post operative maximal incisal opening exceeded 30 mm in 63% of patients and was ranging from 25 to 30 mm in the remaining 37% of patients. Unilateral cases and bilateral cases with short duration of ankylosis showed marked improvement in the functional and aesthetic appearance. Bilateral cases with long standing ankylosis showed less superior results especially as regards relapse and aesthetic appearance and required secondary procedures. Abnormal growth pattern of the graft occurred in 25% of patients with an incidence of 23% of the growing patients and it ultimately ends with recurrence of ankylosis (relapse). Relapse occurred in 37.5% of patients, all of them were bilateral. The causes of this relapse were the long period of intermaxillary fixation, associated extreme muscle shortening and abnormal growth pattern of the graft. Mandibular distraction as another modality for management of this problem eliminates the need for the I.M.F and overcome muscle shortening by progressive stretching of the muscles. Further study of the growth pattern of the graft and how to modify it is required to decrease the incidence of relapse.

### **INTRODUCTION**

The treatment of TMJ ankylosis possess a significant challenge to the maxillofacial surgeon because of its high incidence of recurrence. Failure to alleviate the ankylosis can result in speech impairment, difficulties with mastication, poor oral hygiene, facial and mandibular growth disturbance in children [1].

Treatment usually requires adequate excision of the involved ankylotic block (arthroplasty). This arthroplasty may be a gap arthroplasty without interposing any material or interpositional arthroplasty using autogenous [2-6] or alloplastic materials [7]. In adults, the main objective of condylar reconstruction is to restore lost function and symmetry of the TMJ. In children, there is the added objective of using a graft that has an adequate growth potential [8].

Autogenous costochondral grafts have been used for many years for reconstruction of TMJ and mandible. Gillies [2] described its use since 1920. Poswillo [9] demonstrated the functional similarities, both histologic and physiologic, between mandibular condyle and rib cartilage. MacIntosh and Henny [10] popularized its use. The bony part of the rib is used to replace the condylar neck or ramus and to affix the graft to the mandible, while the cartilaginous portion rests in the existing or newly constructed glenoid fossa. The bone-cartilage junction provides a center with growth potential [8,9,11].

These grafts are usually used as non-vascularized grafts. Their use as vascularized transfers was described in few reports [12-14]. However, there is no significant difference between the two types from the clinical standpoint and the intensity of growth activity [14]. The superiority of the vascularized grafts over the non-vascularized ones is in their ability to produce a newly formed condyle with more anatomical similarity to the normal condyle. Also, they have less potential for poor revascularization, resorption, infection and graft loss.

The technique of costochondral grafting for temporomandibular joint ankylosis has a lot of

variables. These variables include lining of the glenoid fossa [15-22] positioning of the graft [18,23] methods of graft fixation [10,18,20-25] period of I.M.F. [10,18,20,23] thickness of the cartilaginous cap [26,27]. There is also a wide range of clinical results when the ramus is reconstructed with a costochondral graft [8,11,15]. Though these grafts in addition to their growth potential, have all the advantages of autogenous materials for condylar replacement, yet, they still have some disadvantages especially those related to growth pattern and relapse [10,11,15,18,24,28]. Two types of growth were defined by Kaban and Perrott [26]: (1) Linear growth of the ramus-condyle unit that may occur without overgrowth of the articulating surface, this growth results in asymmetrical or symmetrical prognathism without hypomobility. (2) Tumor-like growth of the articulating surface that may occur producing a contour abnormality and deviation of the chin point toward the normal side by a mass effect on the position of the jaw, with mandibular hypomobility or ankylosis. However, the lack of predictability of growth pattern of the costochondral graft is considered to be one of the main disadvantages of the technique [27]. Relapse which is considered to be the most frequent complication of the technique particularly in young patients [22,27,29,30] is rare in other reports [21,23].

So, the aim of this paper is to present our experience with the use of free non vascularized costochondral grafts in management of T.M.J. ankylosis. The surgical technique, advantages and disadvantages as well as the results of long term follow up will be presented and discussed.

## PATIENTS AND METHODS

We treated 16 patients with T.M.J ankylosis (8 males and 8 females) since 1990. At the time of our intervention their ages ranged from 4 to 32 years. Thirteen of them were growing (below the age of 18 years) and only three were non growing (above this age). The duration of ankylosis varied from one to 10 years. Trauma was the cause of ankylosis except one in whom the etiology was not defined. Ten patients had bilateral ankylosis and six had unilateral ankylosis. Pre-operative range of maximum motion at the central incisor (MIO) was 0-12 mm. Twelve patients had a range of 0-5 mm, three patients had a range of 5-10 mm and only one patient had a MIO of more than 10 mm. Ten pa-

tients had previous attempts of release and reconstruction once or more before presenting to us. Two of them were reconstructed by costochondral grafts. Patients' Data are shown in Table (1).

Diagnosis was made by history, physical examination and radiologic examination. Panorex, temporomandibular joint and skull views were routinely done. C.T. Scan (coronal cuts) was done in some cases.

### *Surgical procedure:*

The operative technique was similar to the technique used by Obeid et al. [18]. This included exposure of the TMJ through a preauricular incision. The ankylotic segment is resected creating a gap of not less than 15 mm. The ipsilateral coronoid process is resected. The other joint is not explored unless the achieved mouth opening is less than 25 mm. Exposure of the remainder of the ramus is done through a Risdon submandibular incision. The costochondral graft is harvested from the contralateral side with 5-10 mm cartilaginous cap at the end of the bone (Table 1). Extreme care is done to maintain the perichondrium and periosteum adjacent to and overlying the costochondral junction at the anterior surface. No lining of the glenoid fossa was done. The patient is then put in intermaxillary fixation trying to get the best available occlusion. The costochondral graft would then be placed in position and fixed to the existing portion of the ramus or mandibular body. Fixation is either done along the posterior border or the lateral surface of the ramus using wires (13 patients) or screws (3 patients). The patient is then kept in I.M.F. for a period ranging from 4 to 6 weeks. Two weeks after removal of the L.M.F. vigorous physiotherapy started for the joint.

Any perioperative or early postoperative complications were recorded. Patients were examined clinically and radiologically at 3, 6 and 12 months post-operatively and yearly after. Postoperative evaluation included the maximum incisor opening (MIO), assessment of facial symmetry and maxillary/mandibular relationship. Long term follow-up for the growth pattern of the graft and recurrence of ankylosis will be documented. The period of follow-up was at least one year and extending to 11 years in some patients. Follow up was lost for only one patient 9 months post-operatively.

## RESULTS

Only one patient in this series had post operative infection (6%). This infection was severe and it necessitated removal of one of the two applied costochondral grafts 6 weeks post operatively. This patient developed partial relapse about 2 years after surgery.

Temporary paresis of the temporal branch of the facial nerve (with other branches like zygomatic and mandibular in some cases) occurred in 8 patients (50%). All of them resolved spontaneously within a period of 3 to 10 months post operatively.

The postoperative maximum incisor opening (MIO) was ranging from 25 to 32 mm. It was  $\geq 30$  mm in 10 patients (63%) and more than 25 mm in 6 patients (37%) (Fig. 1). Six out of the 10 bilateral cases (60%) achieved MIO of  $\geq 30$  mm and four (40%) achieved MIO from 25-30 mm. Four out of the 6 unilateral cases (67%) achieved MIO of  $30 \geq$  mm and 2 (33%) achieved MIO from 25-30 mm (Table 1).

In all patients the achieved intraoperative MIO decreased dramatically after removal of the I.M.F, but with physical therapy it reached its original level except in 3 of the bilateral cases that showed further narrowing of the mouth opening ending by reankylosis later on. Two of these patients had severe muscle shortening. In most of the unilateral cases the final MIO usually exceed what was achieved intraoperatively by a percent ranging from 8-28%.

Unilateral cases and bilateral asymmetrical cases with facial asymmetry showed marked improvement with restoration of normal symmetrical faces (Figs. 2,3). Bilateral long standing cases with severe microretrognathia showed moderate elongation of their mandible but did not reach normal appearance (Fig. 4).

All young patients that developed posterior open bite at the time of surgery exhibited closure of this open bite at a variable time later on. All unilateral cases and bilateral cases with short duration of ankylosis showed marked improvement in their occlusion pattern. Bilateral long standing cases despite showing some improvement still have class II malocclusion that will need further intervention later on.

Overgrowth of the graft was seen in 4 patients (25%) (three growing, 23% and one non growing, 33%) and they resulted in variable de-

grees of relapse. All of them were bilaterally reconstructed (Table 1). In two of them there was overgrowth with complete ossification of the cartilage and ultimate bony union that resulted in complete relapse (Fig. 5). In the other two patients the cartilage remained as such without ossification. In one of them this overgrowth was restricted to the cartilaginous portion on one side resulting in partial relapse about one and half years post operatively (Fig. 6). In the other one there was marked hypertrophy of the reconstructed ramus-condyle units that was more on the right side resulting in fusion between the graft and the skull base with complete relapse 10 months post operatively (Fig. 7).

Resorption of the graft occurred in a bilaterally reconstructed case on one side (Fig. 6c). This patient had simultaneous over growth of the cartilaginous portion of the graft on the other side. The patient had severe occlusal disturbance in the long term follow-up (5 years). This was in the form of anterior open bite and lingual cross bite (Fig. 6d).

Relapse occurred in 6 patients (37.5), all of them were bilateral (Table 1) with a percent of 60%. In three of them it was partial relapse where the mouth opening was reduced to 22, 18, 22 mm respectively. The causes were infection and graft loss in one patient, overgrowth of the graft in the second patient and undefined in the third patient due to lost follow up after 9 months. In the other three patients it was complete relapse where the mouth opening was reduced to 5, 0, 3 mm respectively. The causes were over growth of the graft. Two of these patients had associated severe muscle shortening (Fig. 3b).

Of the three patients that had partial relapse, one of them was lost in the follow-up, another one was satisfied by the achieved mouth opening of 22 mm and the third one required secondary procedure. This was the patient who had over growth of the cartilaginous portion of the graft, where shaving of this cartilage was done and the mouth opening increased from 18 to 25 mm. The patient was free for 5 years after the operation and came later on with partial relapse and severe occlusal disturbance with graft resorption on the side.

The three patients who had complete relapse required secondary procedures. In two of them

with complete ossification of the graft and bone fusion bilateral condylectomies and coronoidec-  
tomy with I.M.F (Fig. 5c) were done. In the  
third one with hypertrophy of the reconstructed  
ramus-condyle unit with microretrognathia and  
severe muscle shortening, bilateral mandibular  
distraction was done firstly to elongate the man-

dible and lengthen the shortened muscles (Fig.  
8). Seven months later bilateral condylectomies  
were done for the patient. Intraoperatively the  
graft itself was of normal size with preservation  
and remolding of its cartilaginous portion, but  
the hypertrophy was due to marked bone oppo-  
sition around it (Fig. 9).

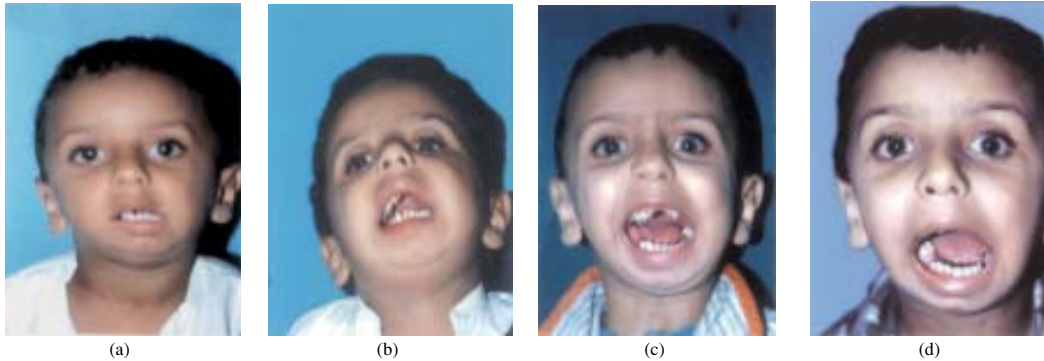


Fig. (1): Patient No. (10) with unilateral left T.M.J ankylosis:  
a- Pre-operative front view. b- Pre-operative mouth opening (4 mm).  
c- Three months post-operative. d- Two years post-operative (mouth opening 28 mm).

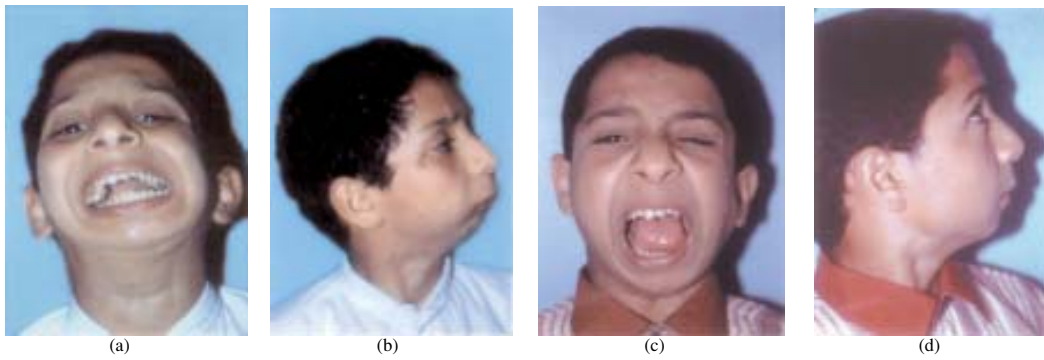


Fig. (2): Patient No. (4) with unilateral left T.M.J ankylosis:  
a- Pre-operative front view (mouth opening 7 mm). b- Pre-operative lateral view.  
c- One year post-operative front view (mouth opening 32 mm). d- One year post-operative lateral view.

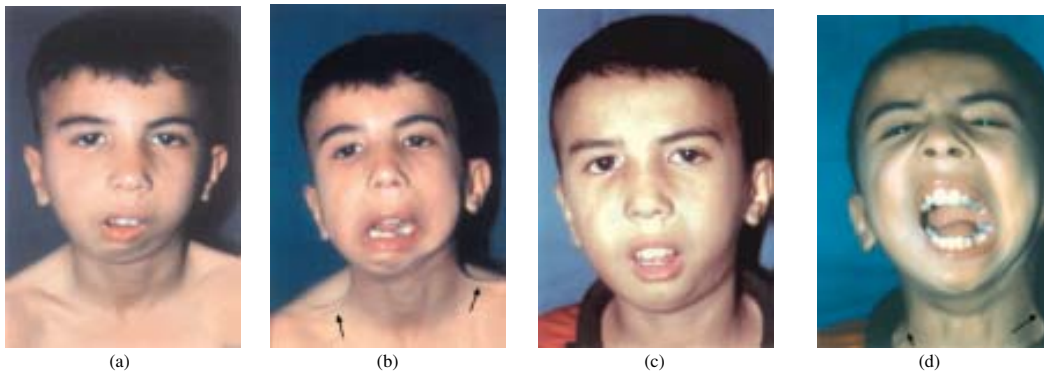

Fig. (3): Patient No. (15) with bilateral T.M.J ankylosis:  
a- Pre-operative front view. b- Pre-operative mouth opening (0 mm) with severe muscle shortening.  
c- 7 months post-operative front view. d- 7 months post-operative mouth opening (25 mm).

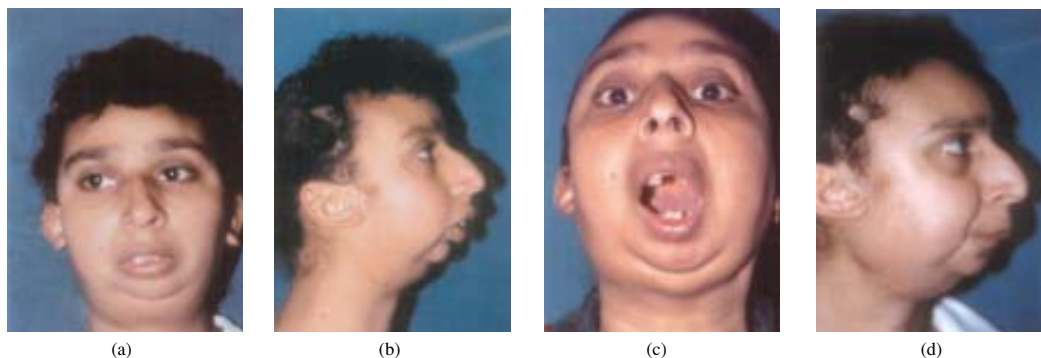


Fig. (4): Patient No. (6) with bilateral long standing T.M.J ankylosis:  
a- Pre-operative front view (mouth opening 0 mm).  
b- Pre-operative lateral view.  
c- One and half year post-operative front view (mouth opening 31 mm).  
d- One and half year post-operative lateral view.

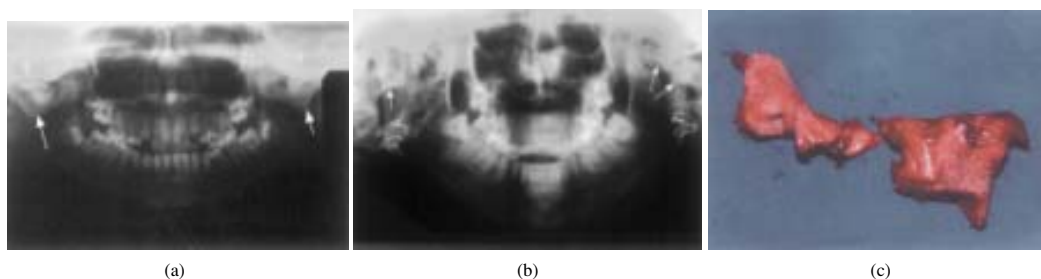


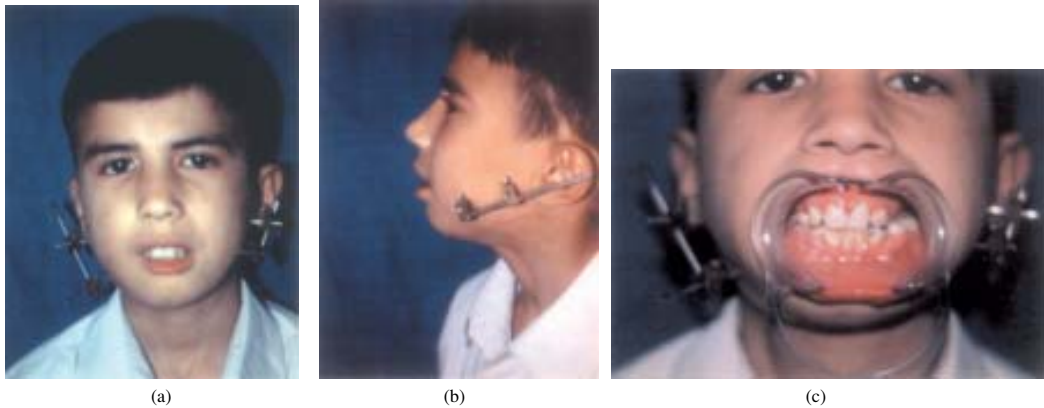
Fig. (5): Patient No. (3) with bilateral T.M.J ankylosis:  
a- Pre-operative panoramic vies.  
b- 7 years post-operative panoramic view showing complete ossification of the cartilaginous portion of both grafts.  
c- The excised callous after bilateral condylectomies.

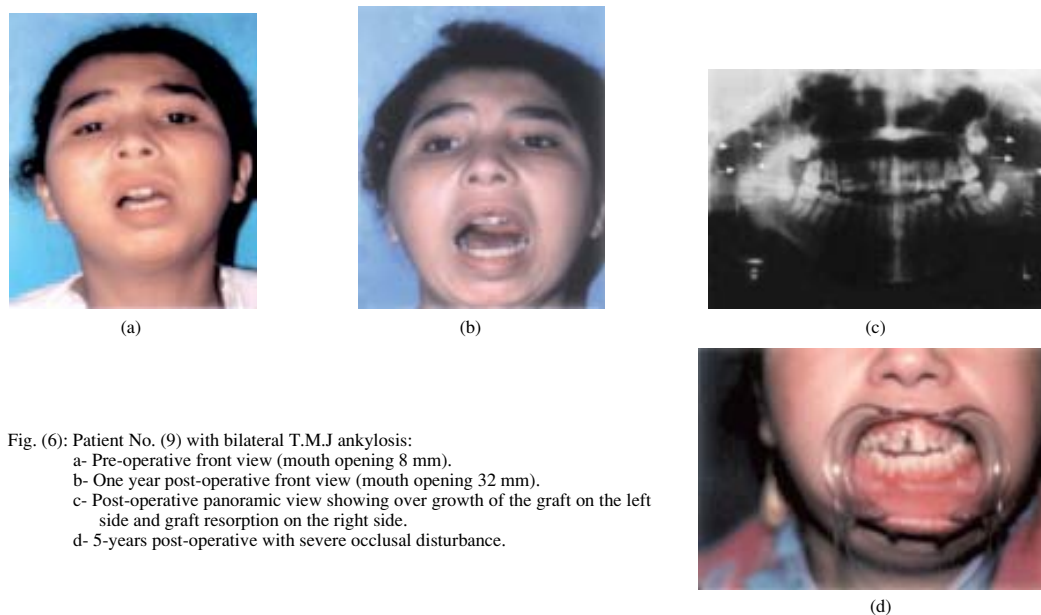
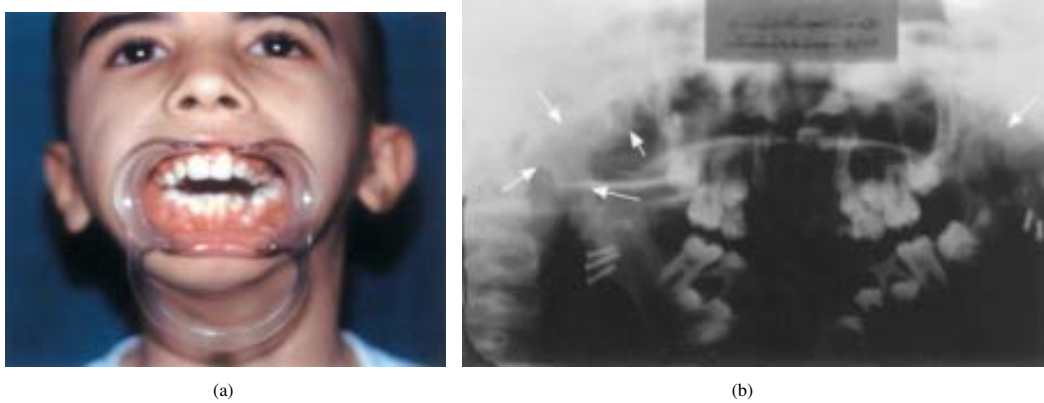
Fig. (6): Patient No. (9) with bilateral T.M.J ankylosis:  
a- Pre-operative front view (mouth opening 8 mm).  
b- One year post-operative front view (mouth opening 32 mm).  
c- Post-operative panoramic view showing over growth of the graft on the left side and graft resorption on the right side.  
d- 5-years post-operative with severe occlusal disturbance.



(a) (b)  
Fig. (7): Patient No. (15) with bilateral T.M.J ankylosis:  
a- 10 months post-operative with complete relapse (mouth opening 3 mm).  
b- Post operative panoramic view showing over growth of the graft on both sides.



(a) (b) (c)  
Fig. (8): Patient No. (15) with bilateral T.M.J ankylosis after the end of bilateral mandibular distraction:  
a- Front view. b- Lateral view. c- Occlusion.

Fig. (9): Patient No. (15) with bilateral T.M.J ankylosis:  
a- Panoramic view showing overgrowth of both grafts with complete fusion and the site of the distracted segment.  
b- Intra-operative view showing the hypertrophied costochondral graft.  
c- The excised graft.  
d- 4 months post-operative front view (mouth opening 30 mm).

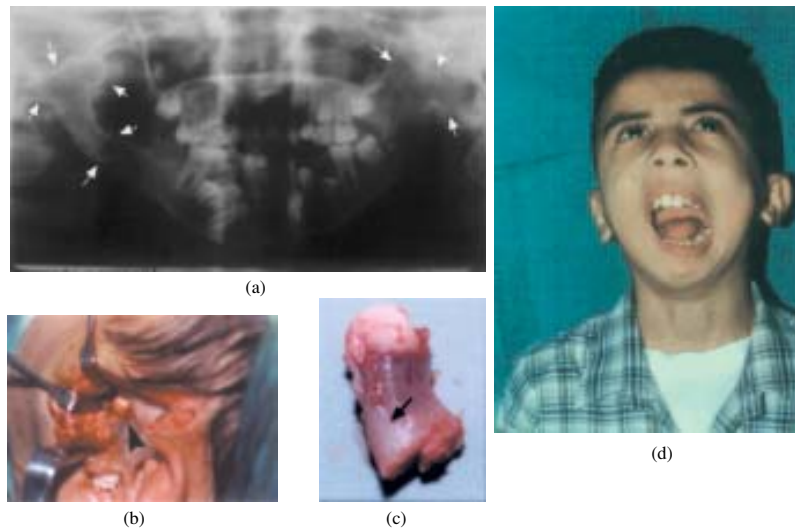


Table (1): Patients' data.

No.	Age	Sex	Uni or bilat	Preop. MIO mm	Post.op MIO mm	Cartilaginous cap	Over growth	Relapse (recurrence)
1	10	F	Bilateral	2	28	7 mm	-	-
2	12	M	Bilateral	3	31	7 mm	-	-
3	10	F	Bilateral	4	25	5 mm	+ (bilat.)	Complete (5 mm)
4	13	M	Unilateral (left)	7	32	10 mm	-	-
5	32	M	Bilateral	0	32	7 mm	+ (bilate.)	Complete (0 mm)
6	24	F	Bilateral	0	31	10 mm	-	Partial (22 mm)
7	16	F	Unilateral (left)	5	28	5 mm	-	-
8	17	F	Unilateral (left)	5	32	10 mm	-	-
9	14	F	Bilateral	8	32	5 mm	+ (left)	Partial (18 mm)
10	5	M	Unilateral (left)	4	28	10 mm	-	-
11	14	M	Bilateral	0	32	10 mm	-	-
12	4	M	Bilateral	4	25	7 mm	-	Partial (22 mm)
13	14	F	Bilateral	0	30	7 mm	-	-
14	13	M	Unilateral (right)	8	30	5 mm	-	-
15	10	M	Bilateral	0	25	5 mm	+ (bilat.)	Complete (3 mm)
16	22	F	Unilateral (left)	12	30	5 mm	-	-

## DISCUSSION

Trauma is still the most common cause of temporomandibular joint ankylosis 80% [31] and 86% [32]. In our series this incidence was 94% of cases.

Costochondral grafts have been used for many years for the management of T.M.J ankylosis there is a lot of debate about many technical points of the technique. Many authors recommended lining of the fossa [15-20]. On other hand Posnick and Goldstein [21] Pensler et al. [22] and ours have not considered this lining to be an important step in consideration of the perichondral cartilaginous cap of the costochondral grafts. They prefer to save the temporo parietal fascia for cases of recurrent ankylosis.

The graft is either pigged inside the ramus or placed along its lateral surface [23] or the posterior border [18]. If the ramus is thick enough to make a deep hole inside it in which the graft will be pigged and wired, this will give a tremendous rigidity. Other factors that we found them determining positioning of the graft were the length of the remaining part of the ramus, the relationship of this part to the fossa and the curvature of the graft itself. Applying the graft on either lateral surface of the ramus or its posterior border makes no difference provided that proper positioning of the cartilaginous cap inside the fossa and a large bony contact are achieved.

Though rigid fixation [20,22] and less rigid

fixation using miniplates and screws [21] were recommended to shorten the period of I.M.F, the majority of authors [10,18,24,25] preferred non rigid fixation using interosseous wires or screws with a variable period of I.M.F. In the experience of Mosby and Hiatt [25] and Posnick and Goldstein [21] rigid fixation has on occasion led to problems. The thinness of the rib cortex results in screw pulling through it or in fractures of the rib graft at the time of application, allowing the potential for movement of the graft. In this series we did not have any of these problems by using either interosseous wires or screws in graft fixation. However, this method has the disadvantage of longer period of I.M.F.

Period of I.M.F varies from 3-10 days with rigid fixation [20] to 6-8 weeks in non rigid fixation [10,18,23]. We are in favor for long period of IMF (at least 4-6 weeks) for better graft fixation and healing as it is one end bone fixation with a small area of bone contact. However, this long period of I.M.F may predispose for recurrence of ankylosis. In all patients false reankylosis occurred immediately after removal of the I.M.F that was overcome by active motion and physiotherapy except in 3 of the bilateral cases. These patients failed to regain the initial mouth opening achieved during surgery and they became reankylosed later on.

Obeid et al. [18] advocated retaining 5-10 cartilaginous cap on the end of the graft to allow keeping the perichondrium and periosteum adjacent to and overlying the costochondral



junction which prevent possible separation of the cartilage from the bone. Kaban & Perrott [26] restricted this portion to only 3-4 mm on assumption that the smaller cartilaginous cap is usually not associated with overgrowth. On the other hand Munro et al. advised to take 1.5-2 cm to maintain the large bony gap created surgically which would prevent recurrence of ankylosis even if the patient was placed in I.M.F for some weeks. This was also recommended to diminish the chance of all the cartilage being converted to bone [27].

A mandibular opening of 30 mm is sufficient to leave patients with little or no functional deficit following reconstruction [18]. This was achieved in 82% of their cases. In this study only 63% of the patients achieved this mouth opening. In the remaining 37% of patients despite that the opening was from 25-30 mm, still it was satisfactory especially for those patients with severe degree of longstanding ankylosis. This final post operative MIO of more than 30 mm is nearly comparable in both unilateral and bilateral cases (67% and 60% respectively). However, in unilateral cases the final result is usually exceeding what was achieved intraoperatively. This can be simply explained by the presence of reversible pathology in the other joint as minimal fibrosis or contraction of the temporalis muscle. This will again emphasize the fact that no forcible opening of the mouth should be done as this will lead to rupture of the fibrosis or temporalis musculature and subsequent scarring with ankylosis of the contralateral side. So, in releasing the ankylosis any value less than 25 mm is an indication for exploration of the contralateral side and the release has to be done according to the nature of the problem [32].

The technique of costochondral grafting proved its efficacy for the reconstruction of the neojoint and for the correction of mandibular hypoplasia in patients having ankylosis associated with hypoplasia [33]. In our series all unilateral cases and bilateral cases with short duration of ankylosis showed marked improvement in the functional and aesthetic appearance. Bilateral cases with longstanding ankylosis achieved less than ideal results especially as regards relapse and aesthetic appearance.

Also, occlusal harmony was achieved in most of the patients. In growing patients the

posterior open bite that is created and maximum at the moment of surgery is closed by supereruption of the maxillary and mandibular dentition and elongation of the posterior half of the maxilla, a previous finding that was reported [34]. On the other hand occlusal disturbance may be the late sequelae of T.M.J reconstruction by costochondral graft. This was seen in one of the bilateral cases. This may be explained by bone flexibility and elasticity that cause deformity of the graft with occlusal changes with time [36]. Another explanation is that though maxillary growth is proportional to the vertical mandibular growth, yet there is no horizontal excessive growth of the maxilla which results in significant shifting of the mandible with mandibular lingual cross bite [27].

The technique has some disadvantages like donor site morbidity, facial nerve injury, the need for IMF, complications related to the graft like possible separation of the cartilage from the bone, occasional fractures, possibility of infection or resorption and unpredictable growth and relapse.

Donor site morbidity with possibility of developing pneumothorax [36] was not seen in any of our patients. The incidence of facial injury which is a complication of the surgical exposure rather than the technique itself was reported to be 50% Politis et al. [17], 33% Rajgopal et al. [31], 17% Nelson and Buttrum [19] and 9% Lindqvist et al. [24]. In this series it was 50% but all of them resolved spontaneously. Infection which was considered to be a common and serious complication [18] occurred only in one of our patients (6%).

The lack of predictability of growth pattern of the costochondral graft is considered to be one of the main disadvantages of the technique [27]. This unpredictability may be in the type, pathology and incidence.

Linear overgrowth was not seen in this study in either growing or non growing patients, a similar finding to the results of Kaban and Perrott [26]. Tumor-like overgrowth was the type of growth that was encountered in most series [27] including our study.

The pathology of over growth was variable; it may be in the form of overgrowth with complete conversion of the cartilaginous portion into bone. This was seen in 2 of our patients



where no cartilage was found in the grafted side. Guyuron and Lasa [27] concluded from this is that the bone and cartilaginous juncture is the source of new bone and the existing cartilage is converted to bone. However the basis for this conclusion is simply clinical observation without histologic analysis [26]. In the other pathological type of growth, the cartilage remained unchanged in nature but it may be abnormally enlarged causing reankylosis or it may not be enlarged but pushed inside the glenoid fossa by marked hypertrophy of the ramus-condyle unit due to marked bone opposition around the graft. This caused reankylosis by obliteration of the fossa and fusion between the bone surrounding the graft and the skull base. So, in any case, the question of whether growth arose from the cartilage, the bony part of the graft, or the basal mandible is largely academic [15].

A review of the literature [10,15,18,24,28,37] shows a total of 60 juvenile patients with graft overgrowth, for a cumulated incidence of 20 percent. This percent is comparable to the results of Kaban & Perrot [26] (2 out of 8 growing patients with a percent of 25%) and the results of this study (3 out of 13 growing patients with a percent of 23%). However, in a single report [27] the incidence was 50% (4 out of 8 growing patients). Some factors are contributing to this great difference as the age of the patients, the thickness of the cartilaginous cap, the stress put upon the graft due to associated muscle shortening and the duration of follow up. In the series of Guyuron & Lasa [27] the thickness of the cartilaginous cap was 1.5-2 cm which is considered to be too much by Kaban & Perrot [26] who limited this thickness to only 3-4 mm. Also, the follow up was long reaching up to 7 years. In our series despite the long term follow up of 10 years we did not have this incidence though using cartilaginous cap of 5-10 mm in thickness. Associate severe muscle shortening in long standing cases may be the cause of stress hypertrophy that was seen in 2 of the recurrent cases.

While some authors found recurrence of ankylosis after surgery is the most frequent complication particularly in young patients Hinds & Pleasants [29], Kennett [30], Guyuron & Lasa [27] (100%) and Pensler et al. [22] 3.5%, this is rare in other reports Posnick & Goldestin [21] 0% and El-Sheikh & Medra [23] 3.7%. In this

series the incidence was 37.5% (6 out of 16 cases) which is still high and even exceeding the results of gap arthroplasty without any interpositional grafts [32].

This may be attributed to many factors including long standing ankylosis causing extreme muscle shortening, very small MIO as in most of the patients it was 5 mm and multiple previous surgical interventions.

*There are many reasons for relapse:*

- 1- Long period of I.M.F.
- 2- Rapid expansion of the shortened musculature which can hamper the desired mandibular length. These two reasons can be avoided by using the technique of mandibular distraction with joint arthroplasty. This will eliminate the need for I.M.F and at the same time by progressive stretching of the adjacent musculature the possibilities of relapse is reduced [38]. This is now our preferable technique in long standing recurrent cases with extreme muscle shortening.
- 3- Conversion of the cartilaginous portion into bone [27].
- 4- Rib/graft overgrowth.

These last two reasons are unpredictable and to guard against them further histological studies are required to detect the exact origin of the growth and how to modify it.

In conclusion costochondral grafting is a very useful technique in the management of temporomandibular joint especially if it is associated with mandibular hypoplasia. All unilateral cases and bilateral cases with short standing ankylosis achieved better aesthetic and functional results than bilateral cases with long standing ankylosis.

The technique has some disadvantages, the most common of them are unpredictability of the growth pattern of the graft and relapse.

Abnormal growth pattern may be related to the age of the patient, thickness of cartilaginous cap and the stress put upon the graft. It is usually ends with reankylosis. Though relapse is common and even exceeding that of gap arthroplasty without any interpositional material, the technique still has its place for the growth po-

tential the graft. Mandibular distraction may achieve better results in cases of long standing ankylosis associated with muscle shortening. This will be presented in another publication.

## REFERENCES

- 1- Adekeye E.O.: Ankylosis of the mandible: Analysis of 76 cases. *J. Oral Maxillofac. Surg.*, 41: 442, 1983.
- 2- Gillies H.D.: Plastic surgery of the face. London: Oxford University Press, 1920.
- 3- Topazian R.G.: Etiology of ankylosis of temporomandibular joint: Analysis of 44 cases. *J. Oral. Surg.*, 22: 227, 1964.
- 4- Synder C.C., Levine G.A. and Dingman D.L.: Trial of sternoclavicular whole joint graft as a substitute for the temporo mandibular joint. *Plast. Reconstr. Surg.*, 48: 447, 1971.
- 5- Bromberg B.E., Walden R.H. and Rubin I.R.: Mandibular bone grafts: A technique in fixation. *Plast. Reconstr. Surg.*, 32: 539, 1963.
- 6- Dingman R.O. and Grabb W.C.: Reconstruction of both mandibular condyles with metatarsal bone grafts. *Plast. Reconstr. Surg.*, 34: 441, 1964.
- 7- Kent J.N., Misiack D.J., Akin R.K., et al.: Temporomandibular joint condylar prostheses: A ten-year report. *J. Oral. Maxillofac. Surg.*, 41: 245, 1983.
- 8- Figueroa A.A., Gans B.J. and Pruzansky S.: Long-term follow-up of a mandibular costochondral graft. *Oral. Surg.*, 58: 257, 1984.
- 9- Poswillo D.: Experimental reconstruction of the mandibular joint. *Int. J. Oral. Surg.*, 3: 400, 1974.
- 10- MacIntosh R.B. and Henny F.A.: A spectrum of application of autogenous costochondral graft. *J. Maxillofac. Surg.*, 5: 257, 1977.
- 11- Ware W.H. and Brown S.L.: Growth center transplantation to replace mandibular condyles. *J. Maxillofac. Surg.*, 9: 50, 1981.
- 12- Dattilo O.J., Granick M.S. and Soteranos G.S.: Free vascularized whole joint transplant for reconstruction of the temporomandibular joint: A preliminary case report. *J. Oral. Maxillofac. Surg.*, 44: 227, 1986.
- 13- Poole M.D.: A composite flap for early treatment of hemifacial microsomia. *Br. J. Plast. Surg.*, 42: 163, 1989.
- 14- Hassanein H.R., Amin M., Badran H.A., Al-Hadded S.I. and Behery M.G.: Reconstruction of defective mandibular condyle in growing children (A clinical study). M.D. Thesis Oral. Surgery. Cairo University, 1991.
- 15- Munro I., Phillips J. and Griffen G.: Growth after reconstruction of the temporomandibular joint in children with hemifacial microsomia. *Cleft Palate J.*, 26: 303, 1989.
- 16- Ohno K., Michi K. and Veno T.: Mandibular growth following ankylosis operation in childhood. *Int. J. Oral. Surg.*, 10 (Supl. 1): 324, 1981.
- 17- Politis C., Fossion E. and Bossuyt M.: The use of costochondral grafts in arthroplasty of the temporo-mandibular joint. *J. Craniomaxillofac. Surg.*, 15: 345, 1987.
- 18- Obeid G., Guttenberg S.A. and Connole P.W.: Costochondral grafting in condylar replacement and mandibular reconstruction. *J. Oral. Maxillofac. Surg.*, 4: 177, 1988.
- 19- Nelson C.L. and Buttrum J.D.: Costochondral grafting for post traumatic temporomandibular joint reconstruction: A review of six cases. *J. Oral. Maxillofac. Surg.*, 47: 1030, 1989.
- 20- Kaban L.B., Perrott D.H. and Fisher K.: A protocol for management of temporo mandibular joint ankylosis. *J. Oral. Maxillofac. Surg.*, 48: 1145, 1990.
- 21- Posnik J.C. and Goldstein J.A.: Surgical management of temporo-mandibular joint ankylosis in pediatric population. *Plast. Reconstr. Surg.*, 91: 791, 1993.
- 22- Pensler J.M., Christopher R.D. and Bewyer D.C.: Correction of micrognathia with ankylosis of the temporo mandibular joint in childhood. *Plast. Reconstr. Surg.*, 91: 799, 1993.
- 23- El-Sheikh m.M. and Medra A.M.: Management of unilateral temporomandibular ankylosis associated with facial asymmetry. *J. Craniomaxillofac. Surg.*, 25: 109, 1997.
- 24- Lindqvist C., Jokinen J., Pauku P., et al.: Adaptation of autogenous costochondral grafts used for temporomandibular joint reconstruction. *J. Oral Maxillofac. Surg.*, 46: 465, 1988.
- 25- Mosby E.L. and Hiatt W.R.: A technique of fixation of costochondral grafts for reconstruction of the temporomandibular joint. *J. Oral. Maxillofac. Surg.*, 47: 209, 1989.
- 26- Kaban L.B. and Perrott D.H.: Unpredictable growth pattern of costochondral graft (Discussion). *Plast. Reconstr. Surg.*, 90: 887, 1992.
- 27- Guyuron B. and Lasa C.I.: Unpredictable growth pattern of costochondral graft. *Plast. Reconstr. Surg.*, 90: 880, 1992.
- 28- Tasanen A. and Leikomaa H.: Ankylosis of the temporomandibular joint of a child. *Int. J. Oral. Surg.*, 6: 95, 1977.
- 29- Hinds C.E. and Pleasants J.E.: Symposium on maxillofacial surgery: Reconstruction of the temporomandibular joint. *Am. J. Surg.*, 90: 931, 1955.
- 30- Kennett S.: Temporomandibular joint ankylosis: The rationale for grafting in the young patient. *J. Oral. Surg.*, 31: 744, 1973.
- 31- Rajgopal A., Banerji P.K., Batura V. and Sural A.: Temporomandibular ankylosis: A report of 15 cases. *J. Maxillofac. Surg.*, 11: 37, 1983.
- 32- Roychoudhury A., Parkash H. and Trikha A.: Functional restoration by gap arthroplasty in temporoman-

- dibular joint ankylosis: A report of 50 cases. *Oral. Surg. Oral. Med. Oral. Pathol. Oral. Radiol. Endod.*, 87: 166, 1999.
- 33- El-Sheikh M.M., MEdra A.M. and Warda M.H.: Bird face deformity secondary to bilateral temporomandibular joint ankylosis. *J. Craniomaxillofac. Surg.*, 24: 96, 1996.
- 34- Kaban L.B., Moses M.H. and Mullken J.B.: Surgical correction of hemifacial microsomia in the growing child. *Plast. Reconstr. Surg.*, 82: 9, 1988.
- 35- Wolford I.M., Cothrell D.A. and Henry C.: Steno claviclar grafts for temporomandibular joint reconstruction. *J. Oral. Maxillofac. Surg.*, 52: 119, 1994.
- 36- Norman J.F., Bramley P., et al.: *Libro de Textoy Atlas en color de La Articulation Temporomandibular*. Barcelona: Labor, pp. 151-171, 200-211, 1993.
- 37- Ware W.H. and Taylor R.C.: Growth center transplantation to replace damaged mandibular condyles. *J. Am. Dent. Assoc.*, 73: 128, 1966.
- 38- Ortiz Monasterio F., Molina F., Andrade L., Rodriguez C. and Sainz Arregui J.: Simultaneous mandibular and maxillary distraction in hemifacial microsomia in adults: Avoiding occlusal disasters. *Plast. Reconstr. Surg.*, 100: 852, 1997.